International Conference Medical and Health Sciences And Life Sciences Conferences 2016

The effect of normal dose extract gempur batu kejibeling (*Strobilanthus crispus*.BL) to Rat's tractus Digestivus

Yoni Astuti[1] , Ali Usodo Mulyo [2]
([1]Universitas Muhammadiyah Yogyakarta, 2.Gadjahmada University)

INTRODUCTION

Strobilanthus crispus

(Acanthaceae) or locally known as pecahbeling

(pecahkaca) has gained great attention due to its high medicinal values. Another name is daun picah beling (Jakarta) enyohkelo, kecibeling, ngokilo in Java. Hei mian Jian jun : Chinese.

The leaves of thia plant are oblong-lanceolate, rather obtuse, and shallowly creante-crispate.

Kecibeling was a traditianlly used for the treatment of diabetes mellitus, diuretic and to treat high blood pressure. Many scientific reports had also proven that S. crispus possessed anti-oxidative, anti-cancer, wound healing anti hiperglicemic properties. *Strobilanthus crispus* contain of potassium, magnesium, sodium,iron, and phosphorous, vitamins (ascorbid acid, riboflavin, and thiamine), phenolic acids (p-hydroxybenzoic acid, p-coumaric acid, caffeic acid, vanillic acid, ferulic acid and syryngic acid), caffeine,tannin,alkaloid, cathecin. S.crispus also contain of cystolith calcium carbonate in which the infuse was mildly alkaline.

.

Objective

This research was carried out to detect the influence of intake extract gempur batu kejibeling for 9 week to the histological of tractus digestivus on rat.

Material and Methods

- *Sohxlet extraction equipment*
- *Extract of strobilanthus crispus, BL I 0 mg/200 gr BB*
- *histological tissue equipment*

- *Twenty male Spraque Dawley rats* ,± 200 grams body weight, 2 m.o. divided into 2 groups: dose I (10 mg),control (aquadest).

- Decapitation was conducted to take tractus digestivus organella.

- Hematoxy-Eosin coloring to detect histological of tissue and cell of Tractus digestivus.

Contact Person: Yoni Astuti. (yoni_astuti@yahoo.co.id)

RESULTS

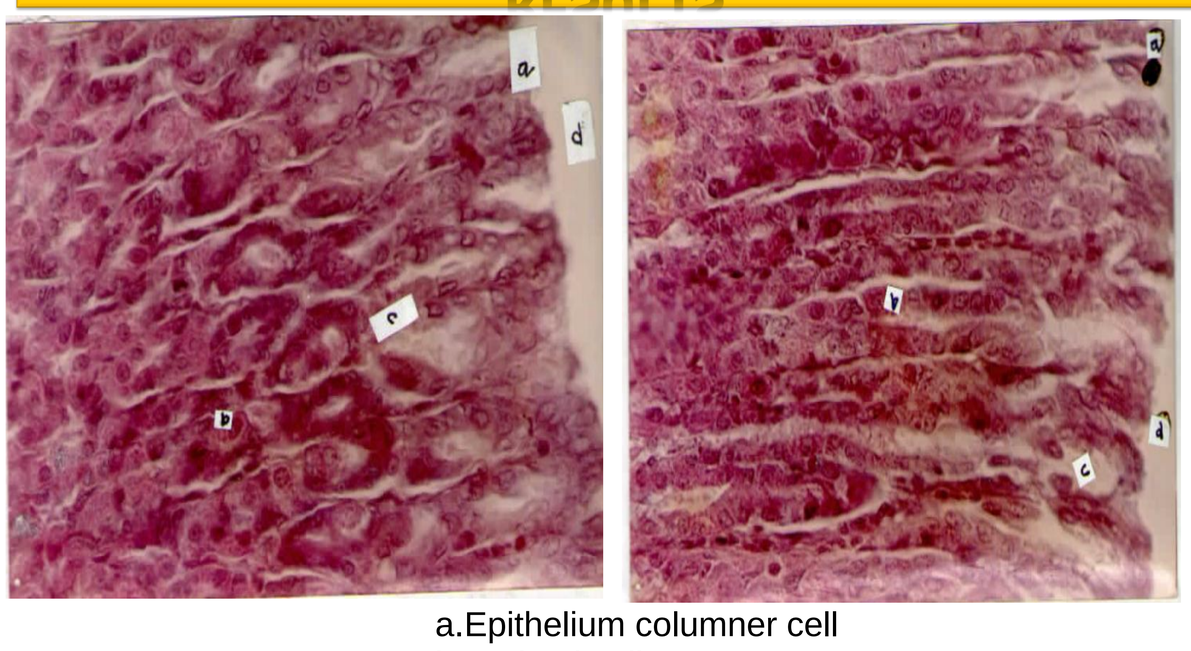

a.Epithelium columner cell
b.Parietal cell
c.Lamina propia
d.Lumen

1A.Ventrikulus , HE, 400X, control (aquadest

1B.Ventrikulus , HE, 400X, 10 mg/200g BB (extract kejibeling)

Figure 1. Histological of ventriculus after intake extract of S. *crispus* for 9 weeks (1a. Control ; 1b 10 mg/200g BB).

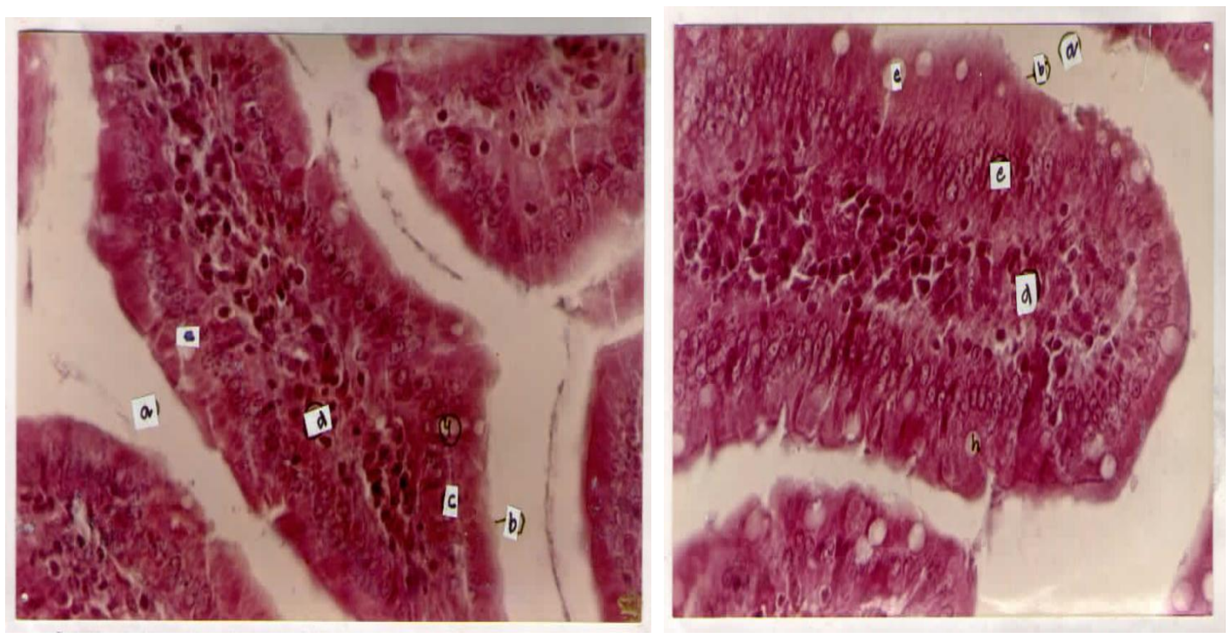

a."Striated border" (microvilli), b. Epithelium Columner cel c.Lamina Propia, d.Lumen , e. Goblet cel

2A. Duodenum, HE, 400X, control (aquadest

2B.Duodenum , HE, 400X, 10 mg/200g BB (extract kejibeling)

Figure 2. Histological of duodenum after intake extract of S. *crispus* for 9 weeks (2a. Control ; 2b 10 mg/200g BB).

DISCUSSION

Strobilantus crispus has Lethal dose 50 for ethanol extract greather than 600mg/Kg BB. The toxic sign observed in the toxicity study was reflected indirectly to the some tissue of organ and systems due to effect of intake oral S.c*rispus*. Below this doses the was not has LD50 effect. This study used normal dose for human, during 9 weeks consumed daily showed hat there were not affect to histological of tractus digestivus

CONCLUSION

Sthrobilantus crispus Extract on various doses (10 mb/200 gBW,20 mg/200 g BW, 40 mg/200g BW)werenot influence histological of rat's tractus digestivus.