

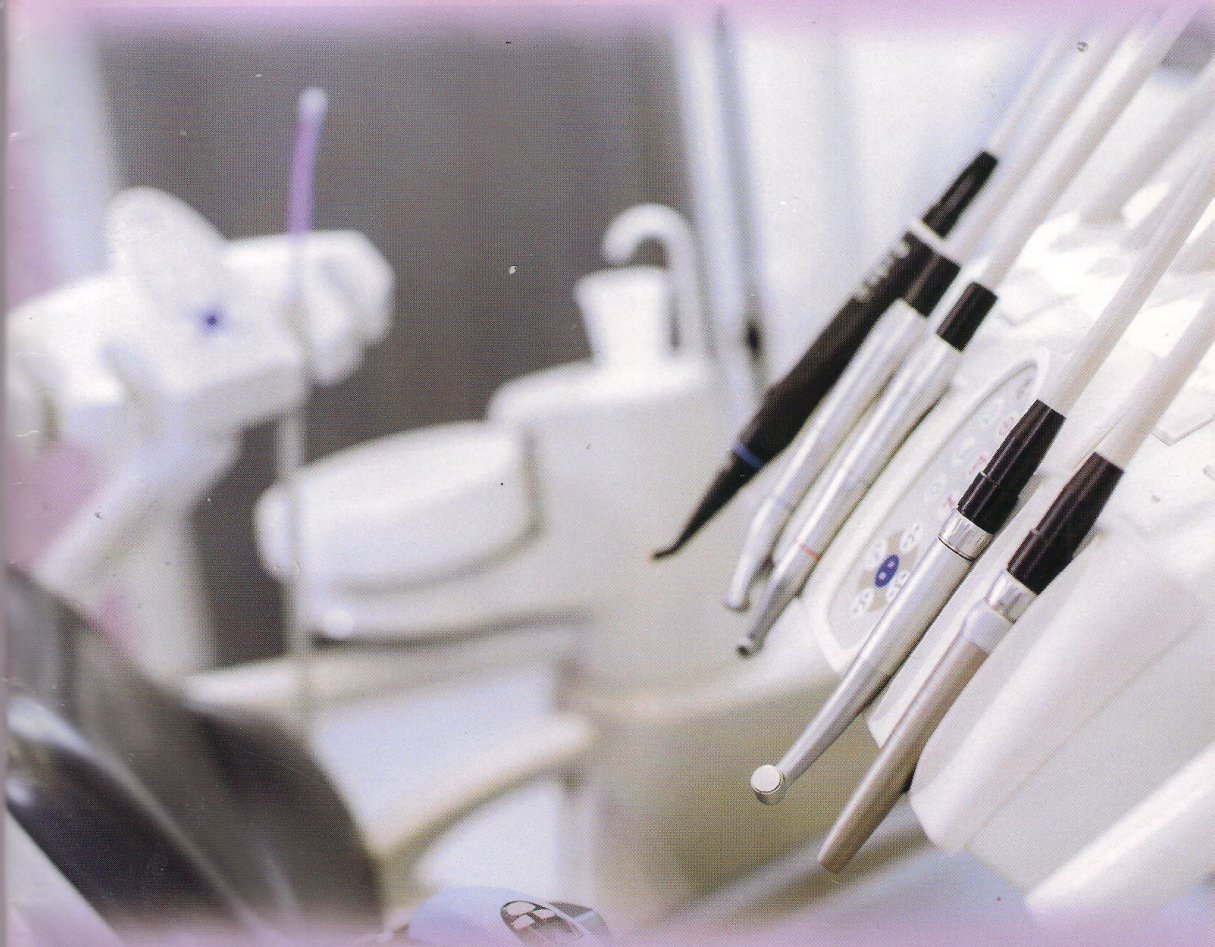Volume 47, Number 1, March 2014

ISSN 1978-3728

Dental Journal

Published quarterly per year

Majalah Kedokteran Gigi



- The role of Hsp60, CD-8 and IFN- γ in immunopathobiogenesis of periapical granuloma in dental caries
- Alkaline phosphatase expression during relapse after orthodontic tooth movement
- The role of heat shock protein 27 (HSP 27) as inhibitor apoptosis in hypoxic conditions of bone marrow stem cell culture

Accredited No. 56/DIKTI/Kep./2012

Dental Journal

Majalah Kedokteran Gigi

CONTENTS

	<i>Page</i>
1. Combination of <i>Aloe vera</i> and xenograft induction on decreasing of NF- κ B of tooth extraction socket preservation in cavia cobaya Utari Kresnoadi and Retno Pudji Rahayu	1-6
2. The role of Hsp60, CD-8 and IFN- γ in immunopathobiogenesis of periapical granuloma in dental caries Risya Cilmiaty and Mandojo Rukmo	7-12
3. The expressions of NF- κ B and TGF β -1 on odontoblast-like cells of human dental pulp injected with propolis extracts Ira Widjiastuti, Ketut Suardita and Widya Saraswati	13-18
4. Spirulina chitosan gel induction on healing process of Cavia cobaya post extraction socket Rostiny, Mefina Kuntjoro, Ratri Maya Sitalaksmi and Sherman Salim	19-24
5. Alkaline phosphatase expression during relapse after orthodontic tooth movement Pinandi Sri Pudyani, Widya Asmara, Ika Dewi Ana and Tita Ratya Utari	25-30
6. Antimicrobial proteins of Snail mucus (<i>Achatina fulica</i>) against <i>Streptococcus mutans</i> and <i>Aggregatibacter actinomycetemcomitans</i> Herluinus Mafranenda DN, Indah Listiana Kriswandini and Ester Arijani R	31-36
7. The effect of immersion in soda on nano hybrid composite resin discoloration M. Chair Effendi, Yuli Nugraeni and Rizki Widya Pratiwi	37-40
8. The role of heat shock protein 27 (HSP 27) as inhibitor apoptosis in hypoxic conditions of bone marrow stem cell culture Sri Wigati Mardi Mulyani, Ernie Maduratna Setiawati, Erma Safitri dan Eha Renwi Astuti	41-44
9. Uji sensitivitas dan spesifisitas perangkat lunak "Prediktor Karies Anak" (The sensitivity and specificity test of pediatric caries predictor software) Quroti A'yun, Julita Hendrartini, Al. Supartinah Santoso, dan Lukito Edi Nugroho	45-51
10. Pengaruh posisi dan fraksi volumetrik fiber polyethylene terhadap kekuatan fleksural fiber reinforced composite (The effect of position and volumetric fraction polyethylene fiber on the flexural strength of fiber reinforced composite) Catur Septommy, Widjijono dan Rini Dharmastiti	52-56
11. Oral hygiene and number of oral mucosal lesion correlate with oral health-related quality of life in elderly communities Dewi Agustina	57-61

Dental Journal

Majalah Kedokteran Gigi

EDITORIAL BOARD OF DENTAL JOURNAL (MAJALAH KEDOKTERAN GIGI)

SK: 059/UN3.1.2/2014

January 2nd – December 31st, 2014

Patron:

Dean of Faculty of Dental Medicine Universitas Airlangga

Advisors:

Vice Dean I, Vice Dean II, Vice Dean III

Chief Editor:

Udijanto Tedjosongko, drg., Ph.D., Sp.KGA(K)
(Pediatric Dentistry – Universitas Airlangga)

Editorial Boards:

Prof. R.M. Coen Pramono D, drg., SU., Sp., BM(K) (Oral and Maxillofacial Surgery – Universitas Airlangga); **Prof. Dr. M. Rubianto, drg., MS., Sp.Perio(K)** (Periodontic – Universitas Airlangga); **Prof. Nairn Hutchinson Fulton Wilson, MSc, Ph.D., FDS** (Conservative Dentistry - University of Guy's Dental School, London); **Prof. W.J. Spitzer, DMD., MD** (Head Department of Cranio & Oral Maxillofacial Surgery Hamburg University, Germany); **Prof. Edward C. Combe, MSc., Ph.D., DDSc** (Biomaterial – Minnesota University, U.S.A.); **Prof. Madya. H. AB. Rani Samsudin, DDS, FDSRC, AM** (Oral and Maxillofacial Surgery - University Sains, Malaysia); **Prof. Widowati Witjaksono, DDS, Ph.D** (Kulliyah of Dentistry, International Islamic University Malaysia); **Prof. Taizo Hamada, DDS, Ph.D** (Prosthodontic - Tohoku University, Japan); **Prof. Yukio Kato, DDS, Ph.D** (Oral Bio Chemistry-University of Hiroshima, Japan); **Prof. Kozai Katsuyuki, DDS, Ph.D** (Pediatric Dentistry – University of Hiroshima, Japan); **Prof. dr. A.G.M. Tielens** (Medical Microbiology – University and Infections Diseases – Erasmus University Medical Centre, Rotterdam, The Netherlands); **Prof. Lakshman Samaranyake** (Oral Microbiology – The University of Hongkong); **Kok Van Kesel** (Medical Microbiology – University and Infections Diseases – Erasmus University Medical Centre, Rotterdam, The Netherlands); **Dr. Leslie Ang** (Restorative Dentistry – National Dental Centre of Singapore); **Prof. Dr. M. Suharsini, drg., MS., Sp.KGA** (Pediatric Dentistry - Universitas Indonesia); **Achmad Gunadi, drg., MS., Ph.D** (Prosthodontic - Universitas Negeri Jember)

Managing Editors:

Prof. Dr. Arifzan Razak, drg., MSc., Sp.Pros (Prosthodontics – Universitas Airlangga); **Prof. Dr. Latief Mooduto, drg., M.S., Sp.KG(K)** (Conservative Dentistry – Universitas Airlangga); **Prof. Dr. Mieke Sylvia M.A.R., drg., MS., Sp.Ort(K)** (Orthodontic – Universitas Airlangga); **Prof. Dr. Istiati Soehardjo, drg., MS** (Oral Biology – Universitas Airlangga); **Prof. Dr. Anita Yulianti, drg., M.Kes** (Dental Material – Universitas Airlangga); **Prof. Seno Pradopo, drg., SU., Ph.D., Sp.KGA** (Pediatric Dentistry – Universitas Airlangga); **Prof. Dr. Diah Savitri Ernawati, drg., M.Si., Sp.PM(K)** (Oral Medicine – Universitas Airlangga); **Prof. Thalca I. Agusni, drg., MHPEd., Ph.D., Sp.Ort(K)** (Orthodontic – Universitas Airlangga); **Dr. R. Darmawan Setijanto, drg., M.Kes** (Dental Public Health – Universitas Airlangga); **Dr. Ely Munadzirah, drg., MS** (Dental Material – Universitas Airlangga); **Priyawan Rachmadi, drg., Ph.D** (Dental Material – Universitas Airlangga); **Dr. Retno Pudji Rahayu, drg., M.Kes** (Oral Biology – Universitas Airlangga); **Dr. Eha Renwi Astuti, drg., M.Kes** (Dental Radiology – Universitas Airlangga); **Bagus Soehadi, drg., MHPEd., Sp.PM** (Oral Medicine – Universitas Airlangga); **Endang Pudjirohani, drg., MS., Sp.Pros** (Prosthodontic – Universitas Airlangga); **Markus Budi Rahardjo, drg., M.Kes** (Oral Biology – Universitas Airlangga); **Dr. Susy Kristiani, drg., M.Kes** (Oral Biology – Universitas Airlangga); **Dr. Ira Widjiastuti, drg., M.Kes., Sp.KG** (Conservative Dentistry – Universitas Airlangga); **Ketut Suardita, drg., Ph.D., Sp.KG.** (Conservative Dentistry – Universitas Airlangga); **Sianiwati Goenharto, drg., MS** (Orthodontic – Universitas Airlangga); **Devi Rianti, drg., M.Kes** (Dental Material – Universitas Airlangga); **Dr. Chiquita Prahasanti, drg., Sp.Perio(K)** (Periodontic – Universitas Airlangga); **Rostiny, drg., M.Kes., Sp.Pros(K)** (Prosthodontic – Universitas Airlangga); **An'nissa Chusida, drg., M.Kes** (Oral Biology – Universitas Airlangga); **Eric Priyo Prasetyo, drg., Sp.KG** (Conservative Dentistry – Universitas Airlangga); **Els Sunarsih Budipramana, drg., MS., Sp.KGA(K)** (Pediatric Dentistry – Universitas Airlangga); **Dr. Hendrik Setiabudi, drg., M.Kes** (Oral Biology – Universitas Airlangga); **Otty Ratna Wahyuni, drg., M.Kes** (Dental Radiology – Universitas Airlangga); **Anis Irmawati, drg., M.Kes** (Oral Biology – Universitas Airlangga); **Yulianti, drg., M.Kes** (Oral Biology – Universitas Airlangga); **Retno Palupi, drg., M.Kes** (Dental Public Health – Universitas Airlangga); **Eka Augustina, drg., Sp.Perio** (Periodontica – Universitas Airlangga); **Febriastuti, drg., Sp.KG** (Conservative Dentistry – Universitas Airlangga); **Mega M. Puteri, drg., Sp.KGA** (Pediatric Dentistry – Universitas Airlangga)

Administrative Assistant:

Novi Dian Prastiwi (Faculty of Dental Medicine – Universitas Airlangga)

Thanks to editor in duty of Dental Journal (Majalah Kedokteran Gigi) Volume 47, Number 1, March 2014:

Prof. Dr. Mandojo Rukmo, drg., MSc., Sp.KG(K) (Conservative Dentistry-Universitas Airlangga)

Prof. Dr. Adioro Soetojo, drg., MS., Sp.KG(K) (Conservative Dentistry – Universitas Airlangga)

Prof. Dr. Jenny Sunariani, drg., MS (Oral Biology – Universitas Airlangga)

Achmad Gunadi, drg., MS., Ph.D., Sp.Pros. (Prosthodontics – Universitas Jember)

Dr. Rini Devijanti, drg., M.Kes. (Oral Biology – Universitas Airlangga)

Kus Harijanti, drg., MS., Sp.PM (Oral Medicine – Universitas Airlangga)

David Buntoro K, drg., MDS., Sp.BM (Maxillofacial Surgery – Universitas Airlangga)

Editorial Address c/o:

Fakultas Kedokteran Gigi Universitas Airlangga
Jln. Mayjen. Prof. Dr. Moestopo No. 47 Surabaya 60132, INDONESIA
Telp. (062-31) 5039478/5030255. Fax. (031) 5039478/5020256
E-mail: dental_journal@yahoo.com Website: www.journal.unair.ac.id

Accredited No. 56/DIKTI/Kep/2012

Cover photo purchased from: www.folia.com
Invoice number: 206708019-204225738

Research Report

Alkaline phosphatase expression during relapse after orthodontic tooth movement

Pinandi Sri Pudyani,¹ Widya Asmara,² Ika Dewi Ana³ and Tita Ratya Utari⁴

¹ Department of Orthodontics, Faculty of Dentistry, Universitas Gadjah Mada

² Department of Microbiology, Faculty of Veterinary Medicine, Universitas Gadjah Mada

³ Department of Dental Biomedical Sciences, Faculty of Dentistry, Universitas Gadjah Mada

⁴ Dentistry Study Program, Faculty of Medicine and Health Sciences, Universitas Muhammadiyah Yogyakarta - Indonesia

ABSTRACT

Background: The increasing of osteoblast activities during bone formation will be accompanied with the increasing expression of alkaline phosphatase enzyme (ALP). ALP can be obtained from clear fluid excreted by gingival crevicular fluid (GCF). Bone turnover, especially bone formation process, can be monitored through the expression of ALP secreted by GCF during orthodontic treatment. Thus, retention period is an important period that can be monitored through the level of bone metabolism around teeth. **Purpose:** This research were aimed to determine the relation of distance change caused by tooth relapse and ALP activities in gingival crevicular fluid after orthodontic; and to determine ALP as a potential biomarker of bone formation during retention period. **Methods:** Lower incisors of 25 guinea pigs were moved 3 mm to the distally by using open coil spring. Those relapse distance were measured and the gingival crevicular fluid was taken by using paper points to evaluate ALP levels on days 0, 3, 7, 14 and 21 respectively by using a spectrophotometer (405 nm). t-test and ANOVA test were conducted to determine the difference of ALP activities among the time intervals. The correlation regression analysis was conducted to determine the relation of distance change caused by the relapse tooth movement and ALP activities. **Results:** The greatest relapse movement was occurred on day 3 after open coil spring was removed. There was significant difference of the average of distance decrease among groups A1-A5 ($p < 0.05$). It was also known that ALP level was increased on day 3, but there was no significant difference of the average level of ALP among groups A1-A5 ($p > 0.05$). Finally, based on the results of correlation analysis between the ALP level decreasing and the relapse distance on both right and left of mesial and distal sides, it is known that there was no relation between those two variables ($p > 0.05$). **Conclusion:** It can be concluded that relapse after orthodontic tooth movement occurs rapidly as the teeth are free from orthodontic force. ALP level can be detected through gingival crevicular fluid during relapse by using a spectrophotometer.

Key words: Relapse distance, alkaline phosphatase, gingival crevicular fluid, guinea pigs

ABSTRAK

Latar belakang: Peningkatan aktivitas osteoblas selama pembentukan tulang akan disertai peningkatan ekspresi enzim alkin fosfatase (Alkaline Phosphatase/ALP). Sumber ALP dapat diperoleh dari cairan bening yang diekskresi celah gingiva gigi yang dikenal sebagai cairan krevikuler gingiva (gingival crevicular fluid/GCF). Bone turnover terutama proses pembentukan tulang dapat dimonitor melalui ekspresi ALP cairan krevikuler gingiva selama perawatan ortodonti. Periode retensi merupakan periode yang penting. Kesulitan memecahkan masalah retensi akan dapat ditangani dengan memonitor tingkat metabolisme tulang disekitar gigi. **Tujuan:** Penelitian ini bertujuan untuk meneliti perubahan jarak relapse gigi dan aktivitas ALP pada cairan krevikuler gingiva setelah digerakkan secara ortodonti dan potensi ALP sebagai biomarker pembentukan tulang pada periode retensi. **Metode:** Gigi insisivus bawah 25 ekor marmot digerakkan ke distal menggunakan opencoil spring sampai mencapai jarak \pm 3 mm, diukur gerakan relapse gigi dan pengambilan cairan krevikuler gingiva menggunakan paper point untuk dievaluasi kadar ALP pada hari ke 0, 3, 7, 14 dan 21 menggunakan spektrofotometer (405 nm). Analisis t-test dan anova untuk mengetahui perbedaan aktivitas ALP antar interval waktu dan analisis regresi korelasi untuk mengetahui hubungan besarnya jarak relapse dengan aktivitas ALP. **Hasil:** Pergerakan relapse yang

paling besar terjadi pada hari ke 3 setelah opencoil spring dilepas. Terdapat perbedaan rata-rata penurunan jarak antar kelompok A1-A5 yang signifikan ($p < 0,05$). Kadar ALP mengalami peningkatan pada hari ke 3, namun tidak terdapat perbedaan rata-rata yang signifikan kadar ALP antar kelompok A1-A5 ($p > 0,05$). Hasil uji korelasi antara penurunan jarak dengan kadar ALP pada mesial distal gigi baik kanan maupun kiri tidak menunjukkan adanya hubungan kedua variabel ($p > 0,05$). **Simpulan:** Relapse pada perawatan ortodonti terjadi secara cepat ketika gigi terbebas dari gaya ortodonti. Kadar ALP dapat terdeteksi dari cairan krevikuler gingiva pada pergerakan relapse gigi menggunakan spektrofotometer.

Kata kunci: Jarak relapse, alkaline fosfatase, cairan krevikuler gingiva, guinea pigs

Correspondence: Tita Ratya Utari, c/o: Ilmu Kedokteran Gigi, Fakultas Kedokteran Gigi Universitas Gadjah Mada. Jl. Denta I, Sekip Utara Yogyakarta 55281, Indonesia. E-mail: tita_utari@yahoo.com

INTRODUCTION

Tooth movement actually occurs in the same direction as bone remodeling response occurs, such as bone resorption which is in the area of pressure and bone apposition on the area of tension in the periodontal ligament.¹ Orthodontic tooth movement is based on biological principle, in which the provision of sustained pressure on teeth will cause alveolar bone remodeling, triggering balance between bone formation occurred at the tension area and bone resorption in the pressure area.²

The results of orthodontic treatment will become so unstable that the use of orthodontic retainer is necessary. These devices are aimed to maintain teeth in a new position after the completion of active treatment and orthodontic appliances has been removed.³ Therefore, treatment during retention period is as important as active period since there is a tendency to return to the previous positions prior to the treatment or relapse.⁴ Relapse in orthodontic treatment can occur quickly, so it is important to provide immediate retention appliance.⁵

Bone remodeling that occurs during orthodontic tooth movement is a biological process that involves an acute inflammatory response in periodontal tissue.⁶ In the initial phase of orthodontic tooth movement, an acute inflammatory response is involved together with periodontal vasodilatation and leukocyte migration out of the blood vessels of periodontal ligament.⁷ Thus, bone remodeling can be considered as complex process, including bone resorption and bone formation requiring the coordination of osteoclasts, osteocytes and osteoblasts.⁸ It means that the provision of orthodontic pressure with continuous force can cause bone resorption and bone formation at the same time since in the pressure area the activities of tartrate-resistant acid phosphatase (TRAP) with positive osteoclasts and osteoblasts will be increasing.⁹ The increasing of osteoblast activities during bone formation then will be accompanied by the increasing of alkaline phosphatase enzyme expressions (alkaline phosphatase/ALP).¹⁰

Alkaline phosphatase is a hydrolase enzyme that works as a phosphatase removing oxygen groups and phosphate groups from many types of other molecules, including nucleotide, proteins and alkaloids. In addition, this enzyme is called as alkaline phosphatase because it works in alkaline

conditions (non-acidic) at pH 10, consequently, sometimes it is referred to basic phosphatase breaking phosphate (mineral acidic) and then creating alkaline pH.¹¹ Besides that alkaline phosphatase is synthesized and secreted by osteoblasts during bone formation, it also catalyzes the hydrolysis of ester phosphatase, which is a potent inhibitor of mineralization process in the alkaline pH associated with the formation of tissue calcification.¹²

Alkaline phosphatase can be obtained from clear fluid excreted from gingival crevicular fluid (GCF). This gingival crevicular fluid can describe body's biological response to periodontal healing process in patients with chronic periodontitis¹³ or can stimulate orthodontic mechanism^{6,13,14} and can be obtained in various ways, such as micro pipetted or paper strips.¹⁵ Gingival crevicular fluid, moreover, is exudate liquid composed of substances derived from various sources, including microbial dental plaque, inflammatory host cells, and host tissue and serum. The last few years, CGF has been used as a diagnostic marker of active tissue destruction in periodontal disease. However, there are only a few researches focusing on the content of GCF involved in bone remodeling during orthodontic tooth movement. Thus, it can be said that ALP expression can describe biochemical changes occurred in supporting tissues after the provision of orthodontic pressure.¹⁶ In some researches, the increasing of ALP levels can be detected during orthodontic tooth movement in week 1 to 3.¹³ Alkaline phosphatase activities in GCF during orthodontic treatment can be associated with treatment time and pressure given on periodontal tissue.¹⁷

Relapse after orthodontic treatment has the same process as orthodontic tooth movement. The positive change of the number of TRAP cells and their distribution along the alveolar bone and molars moved as well as the tooth next to them will cause bone resorption in relapse direction. Simultaneously, new bone formation then will occur in the area opposite to positive TRAP cell activities. It can be said that relapse is like orthodontic tooth movement since in both processes osteoclast differentiation in pressure area is increasing, while that in tension area is decreasing. This indicates that alveolar bone is an important element in relapse process.⁵ In other words, relapse is affected by occlusal instability, increased mechanical tension influenced by transepted fibers and alveolar bone resorption

caused by osteoclasts. Thus, relapse will occur if there is bone resorption caused by osteoclasts.¹⁸

For those reasons, examining gingival crevicular fluid can be considered as a good way to analyze biochemical process continuously occurred in relation to bone metabolism (bone turnover) during orthodontic tooth movement.¹⁹ Examining gingival crevicular fluid can also be considered as a biological evaluation of the results of orthodontic force, so management of tools can be based on tissue response individually, and effectiveness of dental treatment can be improved. Besides that, difficulty to solve retention problem can be addressed by monitoring the rate of bone metabolism (bone turnover) around the teeth. Thus, bone alkaline phosphatase and osteocalcin can be considered as the best marker for bone formation in serum, while deokspiridinolin and n-telopeptida crosslinks as degradation product of collagen secreted through urine can be considered as the most specific marker for systemic osteoclast activity as a bone marker in gingival crevicular fluid.²⁰

In other words, by selecting the appropriate biomarkers of bone turnover, the progress of each individual treatment can be monitored, and the amount of force applied can be modified to prevent iatrogenic effect.²¹ Thus, bone turnover as primarily a process of bone formation must be monitored through the expression of ALP in gingival crevicular fluid during orthodontic treatment.²² The aim of this study were to determine the changes of relapse length and ALP activity on the gingival crevicular fluid after orthodontic tooth movement and to assess whether ALP can be used as a biomarker of bone remodeling on the retention period.

MATERIALS AND METHODS

This research was an experimental laboratory research using 25 local guinea pigs since they can be taken care easily and can survive with a long time treatment. Those animals then became the samples of the research based on certain criteria: weight, male, 6-8 weeks old, 0.5-0.6 kg. Then the application of ethical approval was submitted to the Research Ethics Committee of Dentistry Faculty, Universitas Gadjah Mada. Afterwards, acclimatization of those guinea pigs had were conducted for one week before

they got treatment for adaptation with the place and food in the laboratory

Next, all treatments in this research were conducted in in LPPT unit IV at Universitas Gadjah Mada. Those samples selected were anaesthetized with ketamine (0.1 mg) and xylasin (0.1 mg) by intramuscular injection in thigh of guinea pigs. Then, bonding cleat was inserted on the lower incisors of each sample. Round steel wire with a diameter of 0.016 and an open coil spring with a length of 1.5 times the inter cleat distance were set between the cleats on each samples (Figure 1).

Open coil spring is commonly used in fixed orthodontic treatment for creating space. NiTi wire with the smallest size of 0.010 "x 0.045" and a length of 1.5 times the length between the cleats of the lower incisor was also used. With the compression of the open coil about 25%, force resulted will be 0.25 N-1.3 N, while with the compression of the open coil about 50%, force resulted will be about 0.64N-2.9N.²³ After the tooth moved and the open coil spring was not in passive condition, it was replaced with the new one with the new inter-incisor distance until the distance was about ± 3 mm (usually takes about 14 days). The distance of ± 3 mm was maintained for one week as a period of stabilization.

After one week stabilization, the open coil and the wire were removed. Those twenty-five samples were divided into five groups, each of which consisted of five. The relapse distance of each sample in each group was measured (Figure 2A). Gingival crevicular fluid of each sample in each group was taken on days 0, 3, 7, 14 and 21 respectively. Gingival crevicular fluid was taken by cleaning the lower incisors with cotton to remove supra-gingival plaque, and then those teeth were isolated with cotton rolls and dried. Next, paper points were inserted approximately 1 mm into the gingival sulcus (Figure 2B) of each sample for 30 seconds with an interval of 90 seconds to increase the volume of GCF fluid taken each side, and then immediately inserted eppendorf tubes with the size of 1.5 ml containing 350 μ L of physiological saline solution. Afterwards, those eppendorf tubes were centrifuged for five minutes at 2000 g to elute GCF components completely. Alkaline phosphatase levels contained in the gingival crevicular fluid were measured by using paper points on day 0 (A1), day 3 (A2), day 7 (A3), day 14 (A4) and day 21 (A5). Next, paper points were taken,

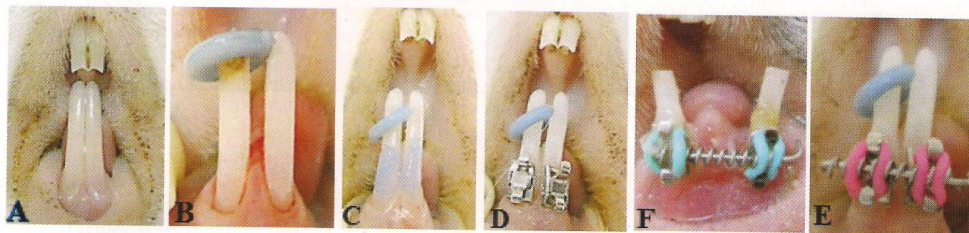


Figure 1. Process of tooth movement: A) lower incisors; B) separator setting; C) etchant application; D) bonding cleat setting; E) open coil spring setting; F) tooth movement.

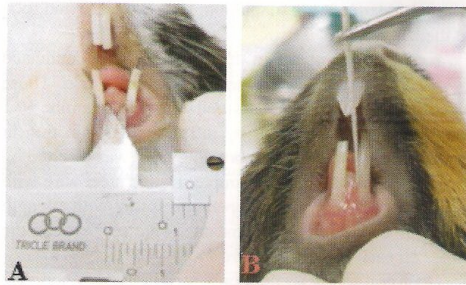


Figure 2. A) measuring the relapse distance using sliding caliper; B) taking gingival crevicular fluid using paper point.

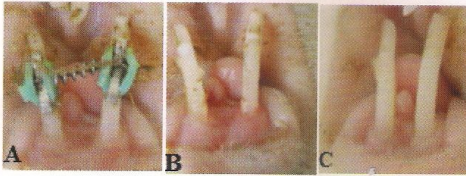


Figure 3. A) tooth movement was finished; B) bracket was removed; C) relapse on day 3.

and then the supernatant solution was stored at -80°C for one week.²² Examination of ALP activities was conducted at Laboratory of Molecular Biology, Faculty of Medicine, Universitas Gadjah Mada.

Alkaline phosphatase activities were determined using a spectrophotometer (Jenway 6330, UK) at a wavelength of 405 nm. Approximately 50 mL of 40 mM carbonate buffer at pH 9.8 mixed with 3 mM MgCl_2 was put into Eppendorf tubes by using pipettes. Fifty mL of GCF samples and 50 mL of 3mm p-nitrophenylphosphate were added to the same tubes. The tubes were then incubated for 30 min at 37°C . The enzymatic reaction was stopped by adding 50 mL of 0.6 M sodium hydroxide, and then the absorbance was measured immediately at a wavelength of 405 nm. The amount of p-nitrophenol formed was measured by using a standard curve prepared from phosphatase substrate (Sigma 104, Sigma-Aldrich, St. Louis, USA). Alkaline phosphatase

Table 1. The average of the decreasing of the relapse distance

	The average of the decreasing of the relapse distance (mm)
from day 0 to day 3	0.8 ± 0.19039
from day 0 to day 7	1 ± 0.15411
from day 0 to day 14	1.7 ± 0.17678
from day 0 to day 21	1.83 ± 0.30332
from day 3 to day 7	0.2 ± 0.24238
from day 7 to day 14	0.7 ± 0.20917
from day 14 to day 21	0.13 ± 0.32519

activities were presented in the form of enzyme unit (U). U is defined as the amount of p-nitrophenol (mol) released per minute at 37°C .²² The data were analyzed by using SPSS, and then the difference of variables between sub-groups was measured with the t-test and ANOVA test. Finally, the relation of the relapse distance and ALP levels was analyzed by using correlation and regression analyses.

RESULTS

The average of the decreasing of the relapse distance after open coil was removed on day 3 was about 0.8 mm (29.2% from the early distance), while on day 7 was 1 mm (37% from the early distance). Moreover, the average of the decreasing of the relapse distance on day 14 was 1.7 mm (51.5% from the early distance), while on day 21 was 1.83 mm (90.1% from the early distance). In other words, it is known that the relapse distance from day 0 to day 3 was 0.8 mm, while from day 3 to day 7 was about 0.2. Furthermore, the relapse distance from day 7 to day 14 was 0.7, while from day 14 to day 21 was 0.13 (Table 1). Therefore, the greatest relapse distance occurred on day 3 after open coil spring was removed (Figure 3).

To determine ALP levels, gingival crevicular fluid was taken from both right and left of mesial and distal sides of those two incisor teeth (Table 2). Based on the data, it is known that significance values obtained were 0.726; 0.432; 0.388; dan 0.724 (>0.05). It means that there was no significant difference of ALP levels among groups A1-A5

Table 2. The average of ALP levels

	ALP Levels (Alkaline Phosphatase) (IU/l) \pm SD			
	Right distal	Right mesial	Left distal	Left mesial
Day 0 (A1)	0.0944 ± 0.11106	0.111 ± 0.15544	0.0296 ± 0.02074	0.267 ± 0.44658
Day 3 (A2)	0.1511 ± 0.24803	0.4568 ± 0.51127	0.071 ± 0.13888	0.2417 ± 0.241
Day 7 (A3)	0.0258 ± 0.00645	0.1232 ± 0.21321	0.0808 ± 0.1089	0.0486 ± 0.05167
Day 14 (A4)	0.07236 ± 0.06431	0.1722 ± 0.23505	0.1438 ± 0.19187	0.0894 ± 0.08476
Day 21 (A5)	0.148 ± 0.13218	0.107 ± 0.15902	0.0622 ± 0.07409	0.1182 ± 0.13054

in both right and left of mesial and distal sides. Based on the results of the correlation test, it is known that there was no relation between the decreasing of the relapse distance and ALP levels in both right and left of mesial and distal sides since the significance value was >0.05 .

DISCUSSION

Based on three-day observation of relapse, it was known that the quickest and greatest movement was on day 3 after orthodontic appliances removed. However, the relapse rapidly occurred only at the beginning of orthodontic appliances removal, since after the next 3 days both relapse distance and its percentage began to decline gradually. Thus, it can be indicated that the same processes occurred at orthodontic relapse movement and orthodontic tooth movement, by increasing of osteoclast differentiation in the pressure area and decreasing of pressure in the tension area. Thus, it can be said that alveolar bone can be considered as an important element in the process of relapse.⁵

It is also known that alkaline phosphatase activities are usually higher in the periodontal ligament than those in the other connective tissue.¹⁴ Thus, to examine the activities, gingival crevicular fluid was taken to determine the level of ALP on day 0 (at the time of cleats and open coil spring removed). The changes occurred directly on the periodontium and the rapid movement in the area of the periodontal ligament were observed to determine the enzyme activities on day 3 after orthodontic appliances removed. It is because on days 7 the enzyme activities are expected to show exactly at the final phase of tooth movement when hyalinisation occurs, and on day 14 and day 21, the enzyme activities are expected to go to the continuation phase or to the final phase.¹⁴

In this research, ALP levels in gingival crevicular fluid was detected by using a spectrophotometer with p-nitrophenol as a standard solution. In general, the enzyme activities generated in this research seemed much less than previous studies likely due to the lack of pressure exerted during the retention period. In this research, acid and alkaline phosphatases were released due to the pressure, injury and death of extracellular tissue fluid. These enzymes produced by the periodontium then diffused in GCF as the result of the application of orthodontic force. Thus, it needs to monitor phosphatase activities in GCF causing tissue changes during orthodontic tooth movement. Similarly, the results of a research on mice shows that phosphatase activities may reflect bone turnover in orthodontic tooth movement.²⁴

The results of the previous research¹⁴ also show that there were significant changes ($p < 0.05$) of alkaline phosphatase activities on days 7, 14 and 21 on both right and left of mesial and distal sides between in the treatment side and in the control side. It is also known that the highest enzyme activities occurred on day 14 in the initial phase, but they were significantly decreased, especially on the

mesial side. Similarly, the results of a research conducted by Yokoya *et al.*²⁵ showed that osteoclasts on the pressure area are increased on day 7, but then they are decreasing rapidly on day 14 when the highest enzyme activities occur. This indicates that ALP activities are followed with tooth movement during initial phase. In contrast, in this research there was no significant difference in ALP levels between groups A1-A5 on both the right and left of the mesial and distal sides ($p > 0.05$). In this research, it is known that the greatest movement occurred on day 0 to day 3, and ALP levels were increased on day 3. However, the decreasing of this relapse distance in this research was not so large since there was no significant difference among groups.

In addition, many clinical researches also showed that there was a correlation between alveolar bone remodeling with changes in phosphatase activities contained in GCF.¹⁷ In this research, there was no correlation between the decreasing of ALP levels on both right and left of mesial and distal sides with the relapse distance ($p > 0.05$). It is also known that the process of bone remodeling with initial resorption activity occurred on days 3-5 days, and repeatedly on days 5-7. The final bone deposition occurred in both the pressure and tension areas on the walls of the alveolar bone on days 7-14. In the initial phase, bone resorption occurs more greatly than bone deposition, but in the next phase, both bone resorption and deposition occurs synchronically.²⁶ ALP levels in this research then were measured when the stabilization of the relapse movement had been done for 1 week so that both bone resorption and deposition were probably already equal. Thus, there was no significant difference among groups or between the mesial and distal sides.

The study showed that orthodontic relapse occurs rapidly when teeth free of orthodontic force. ALP levels can be detected from gingival crevicular fluid during relapse tooth movement using spectrophotometer with a wavelength of 405 so that we can use as a potential biomarker of bone formation in the retention period. There was no correlation between the ALP levels with the relapse distance.

ACKNOWLEDGEMENT

The author wish to thanks the Faculty of Dentistry Universitas Gadjah Mada for grand research Dana Masyarakat 2013.

REFERENCES

1. Krishnan V, Davidovitch Z. On a path to unfolding the biological mechanisms of orthodontic tooth movement. *J Dent Res* 2009; 88(7): 597-608.
2. King GJ, Keeling SD. Orthodontic bone remodeling relation to appliance decay. *Angle Orthod* 1995; 65(2): 129-40.
3. Proffit WR, Fields HW Jr. *Contemporary orthodontics*. 2nd ed. St. Louis: CV Mosby Co; 2000. p. 455.

4. Dyken RA, Sadowsky PL, Hurst D. Orthodontic outcomes assessment using the peer assessment rating index. *Angle Orthod* 2001; 71(3): 164-9.
5. Franzen TJ, Brudvik P, Vandevska-Radunovic V. Periodontal tissue reaction during orthodontic relapse in rat molars. *Eur J Orthod* 2013; 35(2): 152-9.
6. Perinetti G, Paolantino M, D'Attilio M, D'Archivio D, Tripodi D, Femminella B, Festa F, Spoto G. Alkaline phosphatase activity in gingival crevicular fluid during human orthodontic tooth movement. *Am J Orthod Dentofacial Orthop* 2002; (5): 548-56.
7. Davidovitch Z, Nicolay OF, Ngan PW, Shanfeld JL. Neurotransmitters, cytokines, and the control of alveolar bone remodeling in orthodontics. *Dent Clin North Am* 1988; 32(3): 411-35.
8. Su M, Borke JL, Donahue HJ, Li Z, Warhowsky NM, Russel CM, Lewis JE. Expression of connexin 43 in rat mandibular bone and periodontal ligament (PDL) cells during experimental tooth movement. *J Dent Res* 1997; 76(7): 1357-66.
9. Bonafe-Oliveira L, Faltin RM, Arana-Chavez VE. Ultrastructural and histochemical examination of alveolar bone at the pressure areas of rat molars submitted to continuous orthodontic force. *Eur J Oral Sci* 2003; (5): 410-6.
10. Intan ZZA, Shahrul H, Rohaya MAW, Sahidan S, Zaidah ZA. Osteoclast and osteoblast development of *Mus musculus* haemopoietic mononucleated cells. *J Biological Sci* 2008; 8(3): 506-16.
11. Sara F, Saygili F. Causes of high bone alkaline phosphate. *J Mol Biol* 2001; 310(4): 149-54.
12. Stucki U, Schmid J, Hämmerle CF, Lang NP. Temporal and local appearance of alkaline phosphatase activity in early stage of guided bone regeneration. *Clin Oral Implants Res* 2001; 12(2): 121-7.
13. Perinetti G, Paolantonio M, Serra E, D'Archivio D, D'Ercole S, Festa F, Spoto G. Longitudinal monitoring of subgingival colonization by *Actinobacillus actinomycetemcomitans*, and crevicular alkaline phosphatase and aspartate aminotransferase activities around orthodontically treated teeth. *J Clin Periodontol* 2004; (1): 60-7.
14. Batra P, Kharbanda O, Duggal R, Singh N, Parkash H. Alkaline phosphatase activity in gingival crevicular fluid during canine retraction. *Orthod Craniofac Res* 2006; 9(1): 44-51.
15. Ozmeric N. Advance in Periodontal disease markers. *Clin Chim Acta* 2004; 343(1-2): 1-16.
16. Dhoptkar AA, Sloan AJ, Rock WP, Cooper PR, Smith AJ. A novel in vitro culture model to investigate the reaction of the dentine-pulp complex to orthodontic force. *J Orthod* 2005; 32(2): 122-32.
17. Insoft M, King GJ, Keeling SD. The measurement of acid and alkaline phosphatase in gingival crevicular fluids during orthodontic tooth movement. *Am J Orthod Dentofacial Orthop* 1996; 109(3): 287-96.
18. Sadowsky C, Schneider BJ, BeGole EA, Tahir E. Long-term stability after orthodontic treatment: nonextraction with prolonged retention. *Am J Orthod Dentofacial Orthop* 1994; 106(3): 243-9.
19. Isik F, Sayinsu K, Arun T, Ünlüçerçi Y. Bone marker levels in gingival crevicular fluid during orthodontic intrusive tooth movement: a preliminary study. *J Contemp Dent Pract* 2005; 6(2): 27-35.
20. Eyre DR. Bone biomarkers as tools in osteoporosis management. *Spine (Phila Pa 1976)* 1997; 22(24 Suppl): 17S-24S.
21. Krishnan V, Davidovitch Z. Cellular, molecular, and tissue-level reactions to orthodontic force. *Am J Orthod Dentofacial Orthop* 2006; 129(4): 469.
22. Asma AAA, Megat AWR, Zainal ASH. Crevicular alkaline phosphatase activity during orthodontic tooth movement: canine retraction stage. *J Med Sci* 2008; 8(3): 228-33.
23. Brauchli LM, Senn C, Ball J, Wichelhaus A. Force levels of 23 nickel-titanium open-coil springs in compression testing. *Am J Orthod Dentofacial Orthop* 2011; 139(5): 601-5.
24. Keeling SD, King GJ, McCoy EA, Valdez M. Serum and alveolar bone phosphatase changes reflect bone turnover during orthodontic tooth movement. *Am J Orthod Dentofacial Orthop* 1993; 103(4): 320-6.
25. Yokoya K, Sasaki T, Shibasaki Y. Distributional changes of osteoclasts and pre-osteoclastic cells in periodontal tissues during experimental tooth movement as revealed by quantitative immunohistochemistry of H(+)-ATPase. *J Dent Res* 1997; (1): 580-7.
26. King GJ, Latta L, Rutenberg J, Ossi A, Keeling SD. Alveolar bone turnover and tooth movement in male rats after removal of orthodontic appliances. *Am J Orthod Dentofacial Orthop* 1997; 111(3): 266-75.