

Potential ethanol of *Carica papaya* L. extract as immunomodulatory through histology observation at mice balb/C spleen

by Nurul Makiyah

Submission date: 23-Mar-2019 09:4 1AM (UTC+0700)

Submission ID: 1098212715

File name: POTENTIAL_ETHANOL_OF_Carica_papaya_L_EXTRACT_AS.pdf (379.54K)

Word count: 2688

Character count: 14373

POTENTIAL ETHANOL OF *Carica papaya L.* EXTRACT AS IMMUNOMODULATORY THROUGH HISTOLOGY OBSERVATION AT MICE BALB/C SPLEEN

Sri Tasminatun¹, Ria Pravitasari², SN. Nurul Makiyah³

¹ Faculty of Medicine, Muhammadiyah University, Yogyakarta

² Pharmacology Department, Faculty of Medicine, Muhammadiyah University, Yogyakarta

³ Histology Department, Faculty of Medicine, Muhammadiyah University, Yogyakarta

Corresponding Email: riapravi@gmail.com

Abstract: *The diameter of the alba pulp of the spleen will be enlarged, when the body responds to allergens by increasing the activity of the immune system.* Papaya fruits (*Carica papaya L.*) containing flavonoid that can be as an immunomodulator. *This study aims to determine the effect of C. papaya extract to the diameter size alba pulp of the spleen of Ovalbumin (OVA) induced Balb/C mice. The research design was experimental in vivo animal test with post-test only control group design. Thirty male Balb/C mice, ±20grams weight, 8 weeks old, divided into six groups consists of a normal control, negative control, Methylprednisolone, and C. papaya extract treatment group (175mg/kg, 350mg/kg and 700mg/kg dose per day). The extract and Methylprednisolone are given for 28 days, while OVA is given on 15th and 22nd day (intraperitoneal,) and 23rd until 28th day (peroral). On the 29th day the mice are sacrificed and the duodenum was made into histological preparation with HE staining. The immunomodulator effect is assessed by the average of the diameter size alba pulp of the spleen under a light microscope. The data were analyzed using SPSS15 with one way ANOVA continued with Tukey test. The average of the diameter size alba pulp of the spleen for control group is 10,165 ± 0,195; negative control group is 30,357 ± 0,826; methylprednisolone group is 10,220 ± 0,346; 175mg/kgbb dose extract is 14,956 ± 1,057; 350mg/kgbb dose extract is 14,030 ± 0,667; and 700mg/kgbb dose extract is 12,504 ± 0,729. The conclusion of this study is Carica papaya L. extract treatment group (175mg/kg, 350mg/kg and 700mg/kg dose per day) has an effect to the average of the diameter size alba pulp of the spleen in OVA-induced Balb/C mice significantly. 700mg/kg dose per day has the same effect with the methylprednisolone group.*

Keywords: immunomodulator, *Carica papaya L.*, alba pulp of the spleen, ovalbumin

INTRODUCTION

Various types of plants in the tropics have a great potential to be developed as drugs.¹ Aside from being a medicine, tropical plants also can be used as immunomodulators.² Immunomodulators are substances that can boost the immune system due to free radical disorders, bacterial or viral attacks, and can help prevent the occurrence of influenza.² One of the plants that can be developed is the papaya fruit. Papaya (*Carica papaya L.*) is a fruit that is inexpensive, readily available, and are also known as food materials, beverages such as papaya juice, materials for body treatment, fodder and medicines empirically. Papaya fruit contains various types of enzymes, vitamins, and minerals. Vitamin A content more than carrots, vitamin C is higher than oranges. The content of vitamin B complex and vitamin E is also high. Papaya also contains beta-carotene as provitamin A. Besides papaya also contains many active substances, such as flavonoid.³

Compounds that have good prospects in increasing immune system activity are usually from the flavonoid, limonoid, vitamin C, and vitamin E (tocopherol) groups. Results of in vitro testing of the flavonoid class of flavones and flavonols have demonstrated their immune response.⁴

As an immunomodulator, the flavonoid content in plants does not only affect the immune system but also suppress the immune system if the activity is excessive. If immune system activity is reduced, the flavonoids will send intracellular signals to cell receptors to increase their activity. Otherwise, if the immune system works excessively, then the Papaya will be used in reducing the work of the immune system. So herbs containing flavonoids have function in balancing the immune system.²

The body of a living creature itself has the ability to resist various types of organisms or toxins that can damage the tissues and organs of the body. This ability

is called immunity which is the product of lymphoid tissue in the body.⁵ System lymphoid tissue can be classified into two groups, primary and secondary lymphoid organs.⁶ Primary lymphoid organs is an organ that mega-tour of the production and differentiation of lymphocytes and lymphocyte development settings. Secondary lymphoid organs are lymphoid organs that are responsive to antigenic stimulation or where antigen-lymphocyte interactions and their control. Tizard and Guyton classify the spleen as one of the secondary lymphoid organs. The spleen is the lymphoid tissue that forms the largest organ in the animal's body. The spleen has a capsule and trabecula that contains smooth muscle that plays a role in mobilizing blood when physiological activity increases.⁷ Increased activity of the immune system in the spleen, it can be seen from the size of the diameter of the pulp alba spleen. Larger spleen pulp spleen diameter indicates increased activity of the immune system in the spleen.⁸

RESEARCH METHODS

This study is experimental *in vivo* study to examine the potential of extracts of papaya (*Carica papaya L.*) as an immunomodulator in sample animals with post-test only control group design. Subjects were tested animals such as mice Balb / C males, age 8 weeks, body weight \pm 20 grams and obtained from UPHP (Experimental Animal Management Unit) Gadjah Mada University.

Determination of the number of samples required in this study using the calculation with the formula Federer.⁹

As the independent variable is the dose of *Carica papaya L.*, the dependent variable is the diameter of the alba pulp from the spleen mice Balb / C and uncontrollable variables that strain mice Balb / C, male, age 8 weeks and body weight \pm 20 gr were reared in stable condition, the same lighting, and feed with BR I.

The tools used in this study were 1 cc

tuberculin syringe injection, biopsy tools, surgical scissors, a set of tools preparation of histology with HE staining, deck glass, cotton, light microscopy, and optilep.

The research material used is the fruit of papaya (*Carica papaya L.*), methylprednisolone, Ovalbumin (OVA) with Merck brand, BR I feed mice, ethanol extract 80% for manufacturing, 10% formalin for preservation of organs after surgery, 70% alcohol, distilled water, a set of Hematoxylin Eosin coating materials.

The research was conducted at the Integrated Research and Testing Laboratory, Gadjah Mada University in Yogyakarta. The execution begins with the manufacture of ethanol extract of *Carica papaya L.* ethanol extract of *Carica papaya L.* obtained from ripe papaya fruit is sliced thin, dried using freeze drying, crushed into a powder or botanicals and then macerated with 80% ethanol. Ethanol is used as a solvent because ethanol is semi-polar, meaning it can dissolve polar and nonpolar compounds. Flavonoids which are polar compounds are expected to dissolve in the solvent.

Furthermore, the mice were grouped into 6 groups, ie control group, negative control group, C.papaya group dose 175mg / kgbb / day, C.papaya group dose 350mg / kgbb / day, group papaya dose 700mg / kgbb / day and control group positive. As a test of the effects of allergy, the mice were sensitized with OVA intraperitoneally and as a positive control group was the administration of methylprednisolone.

Mice examined 24 hours after the end of OVA exposure and abdominal skin opened with scissors so that the mesentery and peritoneum cavity layer and its contents can be seen clearly. Take the spleen and then stored in 10% formalin and then made preparations for histology were painted using *Hematoxylin eosin* (HE). Preparations observed as much as 10 fields of view with 10x magnification, the observations made on the diameter of the alba pulp spleen using a micrometer measuring instrument. The diameter of the alba pulp is measured vertically and horizontally then averaged.

The research data were then tested for normality distribution using Shapiro Wilk. Then the data were analyzed by one way ANOVA and continued the Tukey test to determine differences between treatments effect in mice.

RESULTS AND DISCUSSION

The results of observations made by recording the diameter of the spleen alba pulp. The results of observation can be seen in Table 1. In Table 1 we get the highest average diameter of spleen pulp in the negative control group of $30.357 \pm 0.826 \mu\text{m}$. The lowest average was in the normal control group of $10.165 \pm 0.195 \mu\text{m}$. While in the group with the treatment of various doses (175mg, 350mg, 700mg) and positive controls had an average size of the pulp spleen of the spleen is lower than the negative control I group (K-OVA).

Table 1. The average diameter of spleen alba pulp (μm)

No.	Groups	Mean \pm SE
1.	K-N	10,165 \pm 0,195 ^a
2.	K-OVA	30,357 \pm 0,826 ^b
3.	K-OVA-CP175	14,956 \pm 1,057 ^c
4.	K-OVA-CP350	14,030 \pm 0,667 ^c
5.	K-OVA-CP700	12,504 \pm 0,729 ^{ac}
6.	K-OVA-MP	10,220 \pm 0,346 ^a

After the data obtained an average diameter of spleen alba pulp and then the data is tested using the Shapiro-Wilk because of the number of samples used ≤ 50 . Shapiro-Wilk Test showed the Sig. all groups > 0.05 , which means the data diameter spleen alba pulp normally distributed. In addition to the variance test obtained by value $p = 0.008 (> 0.05)$ shows that the variance data at the subsequent statistical tests using one way ANOVA to determine whether there is a significant difference from the average diameter of the pulp of the spleen alba six groups. Results of one way ANOVA statistical test showed a p -value = 0.00 ($p < 0.005$), means that there are significant or meaningful differences in average diameter of spleen alba pulp.

In order to find a group that has a significant difference then the researcher did Post-hoc analysis using the Tukey HSD (Honestly Significant Difference). The results of the Post-hoc analysis showed that there are differences in average diameter alba pulp of the spleen between the normal control group with the negative control group, $p = 0.00 (p \leq 0.05)$. This indicates that there are significant differences between the two groups.

The average diameter of the spleen pulp in the negative control group compared with the positive control group had a significant difference ($p = 0.00$).

This suggests that methylprednisolone decreased the diameter of the spleen lymph pulp that was sensitized by ovalbumin. To find a group that has a significant difference then Post-hoc analysis using the Tukey HSD (Honestly Significant Difference) was conducted. The results of the Post-hoc analysis showed that there are differences in average diameter of spleen alba pulp between the normal control group with the negative control group, $p = 0.00 (p \leq 0.05)$. It indicates that there are significant differences between the two groups.

The average diameter of spleen alba pulp in the negative control group compared with the positive control group had a significant difference ($p = 0.00$). This suggests that methylprednisolone decreases the diameter size of the spleen-spleen lymph pulp that was sensitized by ovalbumin.

The results of the other analysis data, the normal control group (KN) on the 700mg / kgbb (K-OVA-CP700) and methylpred-nisolon group (K-OVA-MP) dose group had no significant differences ($p < 0.05$). This is because giving the extract dose 700mg / kgbb and methylprednisolone can suppress immune system activity in spleen so have an average size of the diameter of pulp alba spleen which is almost same with mice that live normal.

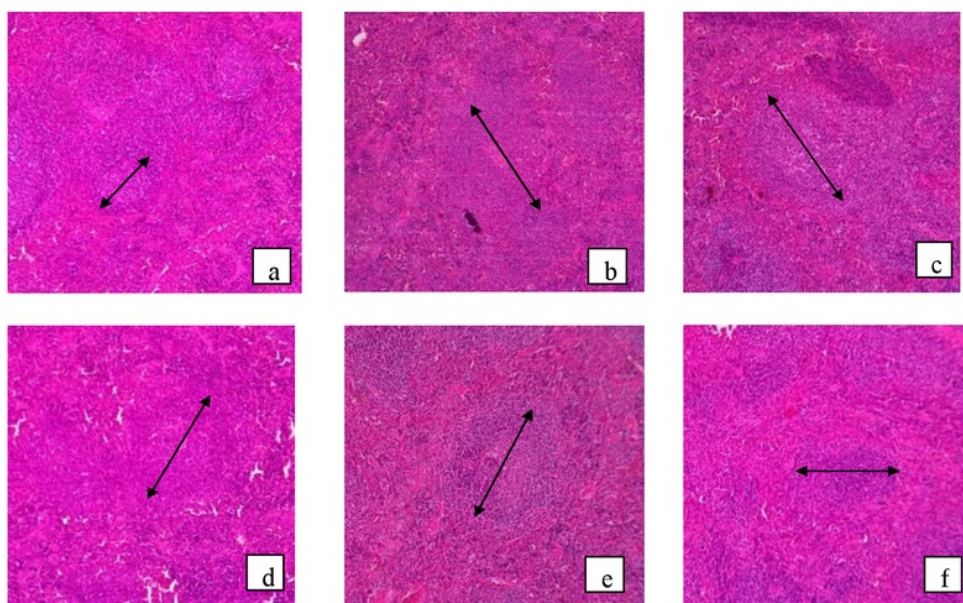


Figure 1. Histology of spleen mice with HE magnification 40x (Description a. KN; b. K-OVA; c.K-OVA-CP175; dK-OVA-CP350; e. K-OVA-CP700; f. K-OVA-MP; the diameter of the alba pulp is indicated by the arrow).

This study showed that ovalbumin as an inflammatory trigger may increase the average diameter of the spleen pulp in the negative control group when compared with the normal control group not sensitized to ovalbumin (Figure 1). OVA by inhalation in allergic animal models proofed cause allergic inflammation and changes in airway structure¹⁰ and ovalbumin also used intraperitoneally as digestive allergy models to increase the relative amount of B220 + IgE + cells in the organs of mice lymph nodes BALB / C0.¹¹

Methylprednisolone is a derivative of prednisolone that has very strong anti-inflammatory properties with fewer side effects when compared with other steroids. The effects of water retention and sodium are very minimal, the effects of gastric irritation are also minimal. Methylprednisolone also inhibits phagocytosis, releasing lysosomal enzymes, synthesis and/or release of some inflammatory chemical mediators.¹²

Papaya contains compounds that

are good enough in increasing the immune system activities, they are flavonoids, limonoid, vitamin C, and vitamin E. Flavonoid is a phenol compound found in almost all plants. Flavonoids have activity as anti-inflammatory, antibacterial because it has a hydroxyl group, allergy activity, and cytotoxic tumor. The activity of flavonoids as anti-inflammatory is through protein denaturation. At high concentrations, flavonoids can inhibit the release of arachidonic acid and secretion of lysosomal enzymes from the membrane by blocking the cyclooxygenase pathway, lipooxygenase, and phospholipase A2. While at low concentrations, flavonoids only block the pathway of lipooxygenase. Low levels of arachidonic acid will reduce the number of inflammatory mediators such as prostaglandins, prostacyclin, endoperoxide, leukotriene, etc. so that the inflammatory process will be inhibited.¹³

CONCLUSION

Ethanol extract of papaya (*Carica papaya L.*) dose of 175mg / kg / day, 350

mg / kg / day and 700 mg / kg / day can decrease the average diameter of the spleen pulp in mice Balb / C, wtaht was induced significantly with ovalbumin. The ethanol extract of dose 700mg / kgbb / day has an effect equivalent to methylprednisolone.

For the future researce it necessary to study the acute toxicity test, sub-chronic and chronic extract of *Carica papaya L.* at various test animals.

REFERENCES

1. Sukara, E. (2000). Sumber Daya Alam Hayati Dan Pencarian Bahan Baku Obat (Bioprospekting). Prosiding Simposium Nasional II Tumbuhan Obat dan Aromatik. [PuslitbangBiologiLIPI, Bogor:31-37.](#)
2. [Suhirman S dan Winarti C. \(2010\). Prospek dan Fungsi Tanaman Obat Sebagai Imunomodulator. Bogor: Balai Penelitian Tanaman Obat dan Aromatik & Balai Besar Penelitian dan Pengembangan Pasca panen Pertanian.](#)
3. Gommay, D. [2](#). (2013). Uji efektifitas pemberian ekstrak daun pepaya (*carica papaya*) terhadap jumlah sel osteoklas tulang alveolar tikus wistar jantan yang diinduksi Porphyromonas [4](#)ngivalis.
4. [Hollman, P.C.H, M.G.L. Hertog and M.B. Katan, \(1996\). Analysis and Health Effects of Flavonoids. Food Chemistry, 57 \(1\) :43-46.](#)
5. GuytonACdanHall.J.E.(2008).BukuAjarFisiologi Kedokteran.Edisi 11.Jakarta:EGC.
6. Tizard IR. (2009). Veterinary Immunology an Introduction. 8th Ed. Masduki P, Penerjemah. Surabaya: Airlangga UniversityPress.
7. Aziza, R. Z. (2010). Gambaran Histomorfologi hati, usus halus, dan limpa pada tikus hiperglikemia yang diberi Ekstrak Sambiloto.
8. Makiyah, S. N. N., Rainy I, Arie N (2014). Pengaruh Paparan Sinar Ultra Violet terhadap Sistem Imun (Histologi Limpa) dan Indeks Mitotik pada Mencit. Jurnal Kedokteran Brawijaya,28(1),pp-17.
9. Prinarbaningrum, A. (2015). Derajat Peradangan Duodenum Mencit Balb/C setelah Pemberian Ekstrak Etanol Ubi Jalar Ungu (*Ipomoea batatas L.*) Diinduksi Ovalbumin. Karya Tulis tidak dipublikasikan. FKIK, Universitas Muhammadiyah Yogyakarta
10. Barlianto, W., Kusuma, M. S. C., Karyono, S., & Mintaroem, K. (2013). Pengembangan Model Mencit Alergi dengan Paparan Kronik Ovalbumin. Jurnal Kedokteran Brawijaya, 25(1),pp-1.
11. Christina, Y. I., & Rifa'i, M. (2014). Aktivitas Ekstrak Etanol Umbi Uwi Ungu (*Dioscorea alata L.*) terhadap Sel B220+ IgE+ pada Mencit BALB/c Model Alergi Pencernaan. Biotropika, 2(2),98-102.
12. Nurudhin, A. (2010). Pengaruh Metilprednisolon Dosis Rendah Terhadap Kadar Hs-Crp Dan C3 Pada Pasien Penyakit Ginjal Kronis Stadium V Pasca Hemodialisis (Doctoral Dissertation, Fakultas Kedokteran [2](#))
13. Dimas, U. B. S., Arina, Y. M. D. A., & Amin, M. N. (2014). Pengaruh Ekstrak Daun Pepaya Terhadap Jumlah Sel Limfosit Pada Gingiva Tikus Wistar Jantan Yang Mengalami Periodontitis (The effect of papaya leaves extract to the number of lymphocytes cells to the male-wistar rat's gingiva that undergo periodontitis). Pustaka Kesehatan, 2(1),50-57.

Potential ethanol of *Carica papaya* L. extract as immunomodulatory through histology observation at mice balb/C spleen

ORIGINALITY REPORT

5%

SIMILARITY INDEX

%

INTERNET SOURCES

5%

PUBLICATIONS

%

STUDENT PAPERS

PRIMARY SOURCES

- 1** E Setyaningsih, Kismiyati, S Subekti. " The effect of noni fruits () with different ripeness stages against the total erythrocytes and leukocytes of comet goldfish () infested by ", IOP Conference Series: Earth and Environmental Science, 2019
Publication 1%
- 2** A T Prasetya, S Mursiti, S Maryan, N K Jati. "Isolation and Identification of Active Compounds from Papaya Plants and Activities as Antimicrobial", IOP Conference Series: Materials Science and Engineering, 2018
Publication 1%
- 3** Domingo, J.L.. "Comparative effects of the chelators sodium 4,5-dihydroxybenzene-1,3-disulfonate (Tiron) and diethylenetriaminepentaacetic acid (DTPA) on acute uranium nephrotoxicity in rats", Toxicology, 19970314 1%

4 Podsedek, A.. "Natural antioxidants and antioxidant capacity of Brassica vegetables: A review", LWT - Food Science and Technology, 200701 **1%**
Publication

5 "Poster Abstracts Others-Published Only", Respirology, 11/2005 **1%**
Publication

6 Nor Azian Ab Rahman, Sagiran Sukardi, Supyan Husin. "A Case Study of Modern Medical Practice and Islamic Complementary Therapy on a Patient with Over 2000 Embedded Nails", International Journal of Public Health Science (IJPHS), 2015 **1%**
Publication

Exclude quotes On
Exclude bibliography Off

Exclude matches < 1%